popular Article

Trends in Agriculutre Science

Vol.1, Issue 9, December, 2022, Page: 408-411

Lumpy skin disease and its emergence in India

K. Madhavi, SN Malleswari Sadhineni and B. K. Kishore Reddy

Krishi Vigyan Kendra, Reddipalle, Acharya NG Ranga Agricultural University

https://doi.org/10.5281/zenodo.7417373

Introduction

A virus belonging to the genus Capri poxvirus, subfamily Chordopoxvirniae, family Poxviridae, is responsible for the infectious condition known as lumpy skin disease (LSD). Diseases typically travel from one area to another via vectors that transfer them mechanically. In most endemic regions, such as sub-Saharan Africa, Egypt, and Ethiopia, the peak activity of vectors coincides with the arrival of seasonal rains and summer. The function of insects as carriers of disease, rather than by direct or indirect contact, has been verified by the decrease in cases during dry conditions with no insects or low insects' density. Several species of ticks, including Amblyomma spp., Rhipicephalus decoloratus, Rhipicephalus appendiculatus, and Amblyomma hebraeum, have been identified as potential repositories and mechanical vectors Animals that drink from and eat from the same troughs are at risk of infection because the virus is shed in bodily fluids like as milk, nasal discharge, saliva, blood, and mucous membrane fluids. LSD is primarily a disease of cattle; Buffaloes develop only mild illness where as domestic animals are considered to be resistant to LSDV infection. The maximum number of deaths due to LSD has occurred in lactating and pregnant cattle, which serve as a direct source of income in terms of the sale of milk and produce progeny, thereby adversely affecting the livelihood of poor farmers in the region

Causative Agent

LSDV of the genus *Capripoxvirus* a disease of Bovines shows similarities with two other Capri pox viruses, sheep pox virus (SPV) and goat pox virus (GPV), which cause similar diseases in sheep and goats, respectively. The above said viruses shows quite similarities both genetically and antigenically and cannot be distinguished from each other serologically. The cross protection against LSDV in instances where LSDV-based homologus vaccine is unavailable is made by use

of Heterologous vaccines (SPV or GPV). In the current Epidemic situation, the Government of India also authorized the use of a heterologous vaccine (GPV-based) against LSD in cattle. However, the use of heterologous vaccines is efficient only upto certain extent by providing partial protection with heterologous Immunization. In general, LSDV is associated with high morbidity and less mortality which is in contrast with high mortality rate by LSDV/2022 starin. The reason for high death rate might be due to Severe haemorrhages, extensive nodules formation all over body especially visceral organs and lungs.

Clinical Findings associated with LSDV infection

The disease is characterized by fever, Lacrimation, Nasal discharge, enlargement of the lymph nodes, anorexia, depression, dysgalactia, emaciation and Characteristic Skin erruptions, development of skin nodules (10–50 mm in size) that can lead to a sharp decline in milk production, abortion in pregnant animal and sterility in bulls. The nodules are well circumscribed, round, slightly raised, firm, and painf**ul** and involve the entire cutis and the mucosa of the GI, respiratory, and genital tracts. Nodules may develop on the muzzle and within the nasal and buccal mucous membranes. The skin nodules contain a firm, creamy-gray or yellow mass of tissue. Regional lymph nodes are swollen, and edema develops in the udder, brisket, and legs. Secondary infection sometimes occurs and causes extensive suppuration and sloughing; as a result, the animal may become extremely emaciated, and euthanasia may be warranted. In time, the nodules either regress, or necrosis of the skin results in hard, raised areas ("sit-fasts") clearly separated from the surrounding skin. These areas slough to leave ulcers, which heal and scar.

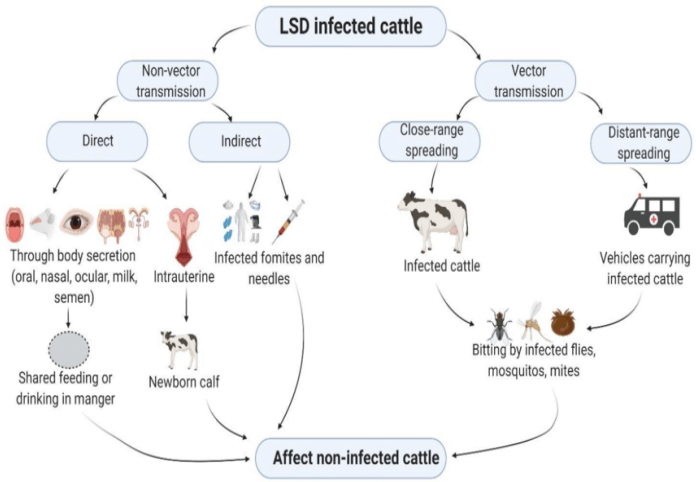

Viability of virus

The virus can survive for a long time in room temperature and humidity. Mummified epidermal shells can keep it alive for 35 days, necrotic lesions for 33 days, and air-dried covers for at least 18 days. While viruses are easily destroyed by sunlight and lipid detergents, they can survive for months in dark environments such as animal shelters and feed shops.

Diagnosis

Diseases including foot-and-mouth disease (FMD), insect bites, demodicosis, and hypersensitivity can mimic the symptoms of LSD clinically. Skin nodules detected on the face, eyelid, neck, snout, nostrils, udder, and limbs might be used to make a speculative diagnosis. A biopsy of the affected skin area might be taken for diagnostic purposes. Skin biopsies also exhibit recognizable pathological alterations, such as vasculitis and perivascular infiltration with white cells that ultimately results in a thrombosis of the vessel in the dermis and subcutis. PCR-based molecular diagnostics is the most accurate and time-saving method currently available for medical diagnosis. The development of both conventional PCR and real-time PCR has facilitated the speedy diagnosis of many diseases.

Prevention and control

There is currently no cure or therapy for LSD. Symptomatic treatment includes the use of antibacterial drugs, anti-inflammatory and supplements which reduce stress and increase appetite.

Restrict movement: Because of the potential for transboundary disease transmission, it is imperative that LSD-infected animals not be moved. If animals with these lesions are found within a country, they should be confined until they can be examined for signs of disease. Vector movement: Disease transmission may occur when vectors are driven around by the wind. Disease prevention can also include the use of vector control strategies, such as vector traps and pesticides.

Vaccination

Like Bovivax and Lumpyvax, the Lumpy Skin Disease Vaccine for Cattle is derived from the Neethling strain. As the LSD virus is closely related to the sheep pox and goat pox viruses, the vaccines against these other diseases can be utilized to protect against LSD. Since the LSD virus is stable and can remain in the environment for a very long time, it is imperative that long-term vaccinations be made mandatory with a 100% coverage rate in order to effectively control and eradicate infection. Lumpi-ProVac$_{Ind}$ can be considered for use to replace the existing goat pox vaccination practice against LSD in cattle in India in addition to conducting epidemiological random

screening in various locations of India to determine the true disease prevalence, researchers in the country should look into the factors that allowed LSD to be introduced there.

References

Gupta, T., Patial, V., Bali, D., Angaria, S., Sharma, M., & Chahota, R. (2020). A review: Lumpy skin disease and its emergence in India. Veterinary research communications, 44(3), 111-118.

Sprygin A, Pestova Y, Wallace DB, et al. Transmission of lumpy skin disease virus: a short review. Virus Res. 2019;269:197637.

Kumar N, Chander Y, Kumar R, et al. Isolation and characterization of lumpy skin disease virus from cattle in India. PLoS One. 2021;16(1):e0241022.

Abutarbush SM, Tuppurainen ESM. Serological and clinical evaluation of the Yugoslavian RM65 sheep pox strain vaccine use in cattle against lumpy skin disease. Transbound Emerg Dis. 2018;65(6):1657–1663.